

ENROLLING CENTER ECHOCARDIOGRAPHY PROCESSING AND SHIPPING

OVERVIEW

Echocardiography (Echo) study is required, if performed per standard of care, for all subjects enrolled in the ARVC study. If Echo is done for diagnosis purposes at the enrolling center after consent form is signed (not previously done by outside source), they should be done using the standardized ARVC Echo protocol in this manual.

ECHO PROCESSING AND PROCEDURES

A screening image set should be sent to the study Echo core lab by each enrolling center to insure that the digital data sets are accessible and interpretable. The study Echo core lab will use this image set to assist the enrolling center with determining how to store and send the raw data.

Echo after Consent is signed: If Echo is performed after the subject has signed the consent form; it is highly recommended that the Echo lab will use the study Echo protocol, and complete the checklist in this manual.

Historical Echo test or Echo that was NOT done using the study Echo protocol: If Echo was performed prior to subject consent, or if the study Echo protocol was not used, the test results should be requested from the Echo Lab that performed the test, and it should be processed as follow:

- The standard images should be exported from the echo machine or PACS and stored in a DICOM standard file with a DICOM directory on CD ROM/DVD or MOD.
- The advanced images must be archived as raw or native data.

SHIPPING ECHO AT BASELINE

Shipping Echo CD / DVD and Reports for a **New** Potential Proband: Echo local interpretation report and forms 5B and 4I must be sent to the Clinical Center PI for ARVC diagnosis. Once the ARVC diagnosis is verified by the Clinical Center PI, the Echo CD/DVD, the Echo local interpretation report, and forms 4A and 4I must be shipped to the Echo core lab. It is possible that the Clinical Center PI will request the Echo images apart from the local interpretation report to assess patient's eligibility, in this case, the Echo CD / DVD must be sent to the Clinical Center PI within 5 working days from date of request.

Shipping Echo CD / DVD and Reports for Family member (old/new) and **Old** Proband: Echo CD / DVD, the local interpretation report, and forms 4A and 4I must be sent to the study Echo core lab in the following cases:

1. The shipment is for a proband from the previous grant.
2. The shipment is for a family member that the proband in the family is from the previous grant.
3. The shipment is for family member AFTER a new Proband in the family is confirmed by the Clinical Center PI.

Please Note: In these cases the Clinical Center PI will NOT verify the ARVC status; therefore, it is required to refrain from sending any data to the Clinical Center PI for family members and old probands.

SHIPPING ECHO AT FOLLOW-UP VISITS

If performed per standard of care, The CD / DVD, the local interpretation report, and forms 4A and 4I should be sent to the study Echo core lab following the procedure, at the next sequential follow-up study visit.

SHIPPING

Initial delivery of the image media, the forms, and the local interpretation report must be attempted by uploading the data electronically, according to instructions in shipping section of this manual. If data upload is unsuccessful, send the data to the Echo Core lab using Fed Ex.

	Items Shipped Baseline Visit		Items Shipped Follow-Up Visit
	➤ New Proband	<ul style="list-style-type: none"> ➤ Old Proband ➤ New Family Member ➤ Old Family member 	<ul style="list-style-type: none"> ➤ Old Proband ➤ New Proband ➤ New Family Member ➤ Old Family member
Ship to Clinical Center PI	<ul style="list-style-type: none"> ➤ Clinical Center Data Shipment Form (Form 5B) ➤ ECHO Form (Form 4I) ➤ Written report 		
Ship to ECHO Core laboratory	<ul style="list-style-type: none"> ➤ Shipping Form (Form 4A) ➤ ECHO Form (Form 4I) ➤ CD ➤ Written report 	<ul style="list-style-type: none"> ➤ Shipping Form (Form 4A) ➤ ECHO Form (Form 4I) ➤ CD ➤ Written report 	<ul style="list-style-type: none"> ➤ Shipping Form (Form 4A) ➤ ECHO Form (Form 4I) ➤ CD ➤ Written report

ARVC ECHOCARDIOGRAPHY PROTOCOL

Echocardiography should be performed with the subject in the left lateral decubitus position. At least three sinus beats of each view should be recorded during quiet respiration or at end expiration. If the subject is in atrial fibrillation at least 5 beats should be recorded. The echo images are required to be recorded digitally and without personal identifiers on the screen (i.e., HIPAA compliant). Specifically, when starting the echo, put only initials or subject number in the name field in the setup menu. The standard images should be exported from the echo machine or PACS and stored in a DICOM standard file with a DICOM directory on CD ROM/DVD or MOD. The advanced images must be archived as raw or native data.

A screening image set is required to be sent to the core lab from each enrolling site to insure that the digital data sets are accessible and interpretable by the core lab. We will use this image set to assist you with determining how to store and send your raw data.

The image media and the local interpretation report (when available) should be sent in protective wrap to the echo core lab by a shipping method that can be traced such as Federal Express. This should be addressed to:

Echocardiography Core Lab
Massachusetts General Hospital, Yawkey 5E
Attn: Dr. Danita Sanborn
55 Fruit St.
Boston, MA 02114-2696

For each view, the gain and compression should be optimized so that the best echocardiographic image of the endocardial borders is obtained. The selection of harmonics or fundamental frequency should depend upon which yields the best definition of structures. The depth should be selected that *allows visualization of all of the structures of interest*. All images should have an ECG tracing and clear calibration markings. If visualization of the RV is inadequate, an intravenous contrast agent either agitated saline or FDA approved microbubbles can be administered to obtain better RV border delineation. For Doppler spectral tracings, the sweep speed should be at least 100 and the scale should be adjusted to make sure that the entire Doppler envelope is visualized.

The RV shape is complex and its inflow, body and outflow portions cannot all be visualized from one view. Thus imaging of the chamber is necessary from several views. The echocardiographic examination should be performed according to a standard procedure (TABLE I):

TABLE I

ECHOCARDIOGRAPHIC EXAMINATION: Methods

- 1) Parasternal long axis
- 2) Parasternal long axis to visualize the tricuspid valve (RV inflow view)
- 3) Parasternal short axis (multiple levels including the base of heart to visualize RVIT and RVOT)
- 4) Apical four-chamber (taking care that all walls of LV and RV are viewed throughout systole and diastole)
- 5) Apical two-chamber (left ventricle, again taking care that image is not foreshortened and all walls are visible throughout systole and diastole)
- 6) Subcostal long axis
- 7) Subcostal short axis of RV inflow and outflow

Specific Imaging Techniques

Standard Images

1) The first echocardiographic window that should be obtained is the **parasternal long axis**. This imaging plane is recorded with the transducer in the third or fourth intercostal space immediately to the left of the sternum. The transducer should be angled so that aortic valve, mitral valve and left ventricle are in their long axis. This view should be performed at a depth that allows visualization of all structures and then at a lower depth focusing on the RV.

Structures of interest in this view include:

- Left ventricle - dimensions and wall motion

- Left atrium - size
- Mitral valve – structure and function
- Aortic valve – structure and function
- Right ventricle - dimension, morphology and wall motion

In this view, M-mode of the LV should be obtained at the highest sweep speed. The line of interrogation should be at the leaflet tips and perpendicular to the long axis of the LV.

Color Doppler of the MV and AV should be obtained.

2) The second view is the parasternal long axis of the RV which allows visualization of the tricuspid valve (**RV inflow view**). This is obtained by angling the transducer to the right from the parasternal long axis of the LV and rotating the transducer slightly. The inferoposterior wall of the right ventricular inflow tract under the tricuspid valve is the most important region to be visualized, because it is a frequently affected region. To evaluate this region the transducer should be angled toward the inferior vena cava or the liver. In ARVC this region may appear as thinned and have diastolic bulging or wall motion abnormalities (hypokinesis, akinesis or dyskinesis). In ARVC subjects the inferoposterior wall motion is generally reduced as compared to healthy subjects. In severe ARVC the only motion in this region is that of the leaflet plane. Color Doppler of the TR jet should also be attempted.

3) The **parasternal short axis** at the aortic valve level is obtained by angling the probe 90° with respect to the parasternal long axis of the LV. This view provides information about the outflow portion of the right ventricle. In many subjects the ratio between the right ventricular outflow tract and the aorta (in systole) will be enlarged. The outflow tract is one of the places where there are saccular dilatations and wall motion abnormalities. Prominent or hypertrophied RV trabeculations have been described on echo. The anterior wall of the RV, especially in its apical portion, may be commonly affected by fibrofatty replacement. Therefore, it is important to view the anterior wall of the right ventricle from several short axis views including mid-ventricle and apex. These are obtained by angling or moving the probe more toward the apex while maintaining a tomographic cut of the LV. These views are important for the analysis of the left ventricle and septal configuration.

Color Doppler of pulmonic regurgitation and a peak velocity of the tricuspid regurgitation jet by continuous wave Doppler should be obtained from the short axis views of RV outflow and inflow respectively. Continuous wave Doppler of the pulmonic valve is obtained from the short axis of the RV outflow for calculation of RV myocardial performance index (Tei index).

4) The **apical four-chamber** view provides considerable information including the relative sizes of the right and the left ventricle. The four-chamber view is defined as a view which maximizes the LV long axis and the tricuspid and mitral annular dimensions. In this view, the full excursion of the mitral and tricuspid valves should be seen. From this view, the morphology and the motion of the left ventricle and right ventricle are assessed. In order to permit visualization of the trabecular pattern of the RV, an image should be obtained by moving the transducer toward the midline and magnifying the RV.

In the apical four chamber view, color Doppler of mitral regurgitation and tricuspid regurgitation should be recorded. Also pulse wave Doppler at the leaflet tips of the mitral and tricuspid valves should be recorded at the fastest sweep speed in order to assess diastolic function. Pulse wave Doppler of a pulmonary vein should be recorded when feasible. Lastly, the continuous wave Doppler of the tricuspid regurgitation jet should be recorded in order to calculate the peak RV systolic pressure.

5) The echocardiographic analysis continues with the study of the **subcostal long-axis view**. This view is obtained with the transducer moved to a subxyphoid position and directed superiorly and leftward. The view is aligned so that the orientation of the LV and RV are similar to that obtained in the apical four chamber view. From this subcostal long-axis view one can obtain information about the RV size and motion of its free wall and apex. The transducer is then angled upward to visualize the shape and motion of the RVOT and to assess for saccular dilatation and wall motion abnormalities.

6) Finally the transducer is rotated into the **subcostal short axis view**. From this projection both the inflow tract and the outflow tract of the right ventricle are assessed. Again in this view key findings of AVRD include alteration of motion such as diastolic bulging or wall motion abnormalities of the inflow tract and enlargement, and saccular dilatation of the outflow tract.

The compilation of these views will allow for calculation of:

- Cardiac chamber dimensions (including LV, LA, RA and RV)
- Left ventricular volumes and mass
- Left ventricular global and regional function
- Right ventricular areas and volumes (RV volume will be calculated by 3-d imaging when of adequate quality)
- Right ventricular global and regional function
 - ◆ systolic: calculated by “descent of the base” method (TAPSE), endocardial fractional area change method, and volume change
 - ◆ diastolic: TV E/A wave, TV deceleration time, $-dP/dt$ from TR
 - ◆ TV annular tissue Doppler – systolic and diastolic and ratio with TV velocities

- Right ventricular wall thickness
- Severity of tricuspid valve regurgitation
- Estimation of the right ventricular systolic pressure
- Right ventricular regional function
- Presence and location of RV aneurysms

Advanced Doppler Echocardiography: Tissue Velocity, Strain and Strain rate

Tissue Doppler echocardiography is a variation of conventional Doppler flow imaging that allows quantification of the Doppler shift within the range of myocardial tissue motion. The velocity and direction of a variety of myocardial sites can be characterized using Doppler techniques. Doppler Tissue Velocity, Strain and Strain rate of both the LV and RV walls will be measured. Color TDI and pulsed wave TDI as well as speckle tracking will be performed:

For pulsed wave TDI, sample volumes are positioned at basal level of the interventricular septum and lateral wall of LV from the apical 4 chamber view. Peak systolic (S1, early diastolic (E') and end-diastolic (A') waves are measured.

From color TDI three complete cardiac cycles from each echocardiographic view will be collected and stored in a cine loop format. Care will be taken to insure that the walls being analyzed are parallel with the ultrasound beam and that **the frame rate during color TDI is > 140 fps**. In the apical views, each LV and RV wall that is analyzed is divided into 3 segments: basal; mid; and apical. The TDI data sets will be used to obtain the following measurements:

- a) regional myocardial wall velocity
- b) strain rate
- c) strain

For speckle tracking, two-dimensional images will be obtained with special care taken to insure visualization of both endocardial and epicardial surfaces. **Frame rates for speckle tracking will be optimized between 40-80 fps**. The views obtained for LV and RV analysis will include PSAX at base, mid-papillary muscle and apex for both LV and RV; apical 4 chamber view with focus on LV and then on RV, and apical 2 chamber view for LV.

Note: These advanced Doppler images must be archived (stored on media) as “raw” or “native” data in order to enable offline quantification.

Three dimensional echocardiography

Three dimensional (3D) echocardiographic analysis will be performed to determine if measurements can provide a more accurate characterization of the phenotype than standard 2D echo methods.

Harmonic real time 3D echocardiograms will be performed using a Philips iE33 system or GE Vivid 7 or E9. Full volume 3D data sets from apical view are obtained by averaging 4 consecutive heart beats. The 3D echo data sets will be used to obtain the following measurements:

Left Ventricle: a) end-diastolic LV volume, b) end-systolic LV volume, c) LV ejection fraction, d) LV mass, e) wall motion score index, f) dyssynchrony index

Right ventricle: a) end-diastolic RV volume, b) end-systolic RV volume, c) RV ejection fraction, d) RV mass

Atria: a) left atrial volume, b) right atrial volume

Note: These 3-D images must be archived (stored on media) as “raw” or “native” data in order to enable offline quantification.

**ECHOCARDIOGRAPHY
CHECKLIST FOR GENETICS OF ARVC**

1. Parasternal long axis

_____ 2-D imaging: 3 sinus beats focusing on LV/LA/LVOT/Ao
_____ 2-D imaging: 3 sinus beats focusing on the RV
_____ Color Doppler: MV and AoV
_____ M-mode: through the mitral leaflet tips

2. Parasternal Long Axis of the RV inflow (RVIT)

_____ 2-D imaging: 3 sinus beats of the TV leaflets and RV function and wall motion
_____ 2-D zoom: on the RV side of the TV - 3 beats for wall motion and structure (looking for posterior RV wall aneurysms)
_____ Color Doppler: of the TR

3. Parasternal Short Axis at the Base

_____ 2-D imaging: 3 sinus beats of high quality non-focused view
_____ 2-D zoom: Focusing on the RVIT
Focusing on the RVOT
Focusing on the PV/PA
Focusing on the AoV
_____ Color Doppler: RV inflow
RV outflow
Pulm Valve
PA
_____ Spectral Doppler: TR (CW)
PV (CW)

4. Parasternal Short Axis at the Mitral and Tricuspid Valve levels

_____ 2-D imaging: 3 sinus beats to assess wall motion of both LV and RV
Note: *Frame rates for speckle tracking optimized between 40-80 fps*

5. Parasternal Short Axis at the LV Mid-ventricle (try to have RV and LV in view)

_____ 2-D imaging: 3 sinus beats to assess LV and RV size and wall motion
Note: *Frame rates for speckle tracking optimized between 40-80 fps*

6. Parasternal Short Axis at the LV Apex (try to have RV and LV in view)

_____ 2-D imaging: 3 sinus beats to assess LV and RV size and wall motion
Note: *Frame rates for speckle tracking optimized between 40-80 fps*

7. Apical 4 Chamber

- _____ 2-D imaging: 3 sinus beats of all 4 chambers for relative size and function
Note: Frame rates for speckle tracking optimized between 40-80 fps
3 sinus beats focusing on RV
3 sinus beats focusing on TV
- _____ M-mode: of the lateral (free wall) TV annulus for TAPSE calculation
- _____ Color Doppler: Mitral inflow and regurgitation
Tricuspid Inflow and regurgitation
- _____ Spectral Doppler: CW of MR optimizing scale and gain to see entire envelope
CW of TR optimizing scale and gain to see entire envelope
PW of mitral inflow (E and A waves)
PW of tricuspid inflow (E and A waves)
- _____ Tissue Doppler: of the mitral and tricuspid annulus- free walls and septal (optimize scale and baseline of the image so both systolic and diastolic waves can be measured) Note: the frame rate during color TDI is > 140 fps
- 3-D full volume:
- _____ 4 beat acquisition with entire LV in view avoiding stitch artifacts if possible
- _____ 4 beat acquisition with entire RV in view avoiding stitch artifacts if possible

8. Apical 5 Chamber

- _____ 2-D imaging: 3 sinus beats focusing on LVOT/Aorta
- _____ Color Doppler: Through LVOT/AoV
- _____ Spectral Doppler: LVOT (PW) just below AoV
Aortic Valve (CW)

9. Apical 2 Chamber

- _____ 2-D imaging: 3 sinus beats for LV wall motion
Note: Frame rates for speckle tracking optimized between 40-80 fps
- _____ Color Doppler: of the MR

10. Apical 2 Chamber of RV

- _____ 2-D imaging: 3 sinus beats for RV wall motion
- _____ Color Doppler: of TR

11. Subcostal Long Axis

- _____ 2-D imaging: 3 sinus beats to focus on RV free wall and apex function
- _____ Color Doppler: of Interatrial septum and TV/MV

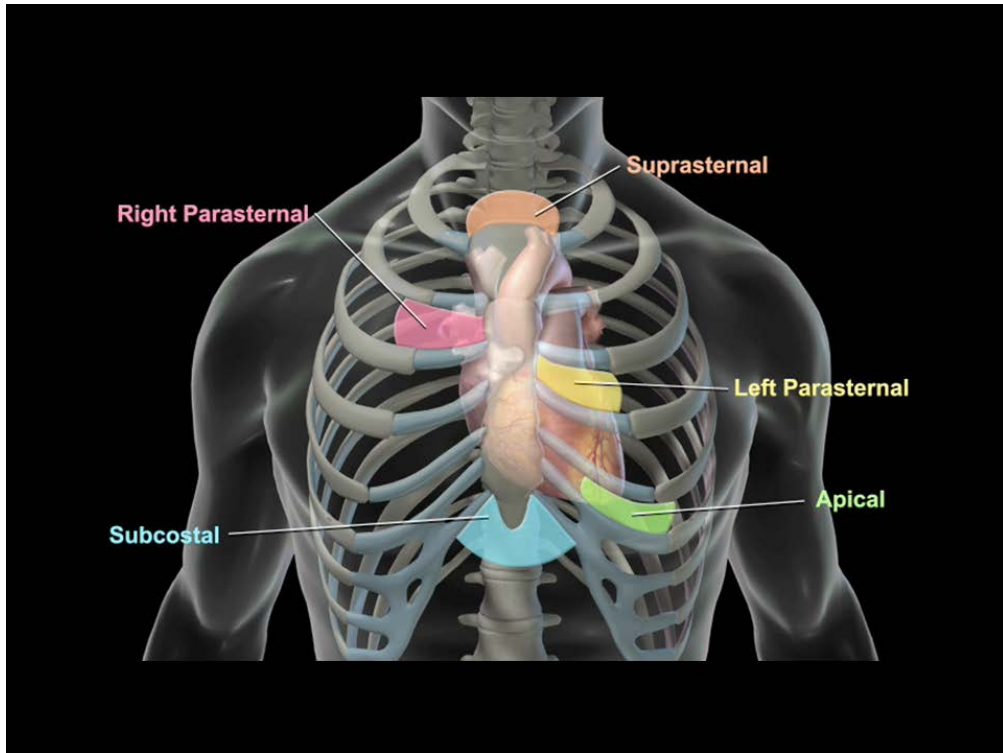
12. Subcostal Short Axis

- _____ 2-D imaging: 3 sinus beats to view RVOT and RVIT
- _____ Color Doppler: of TV and PV

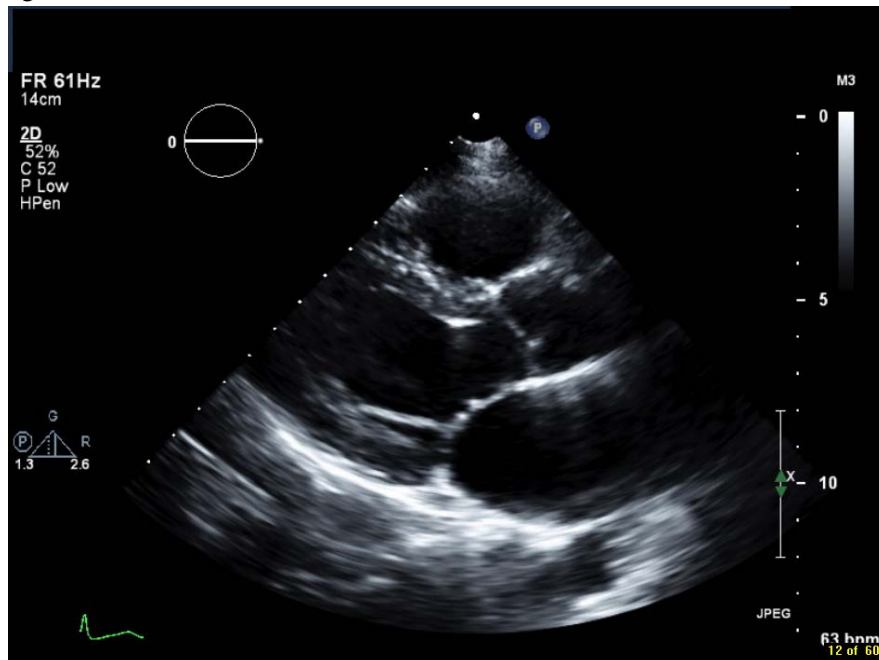
Note: For detailed information regarding standard TTE views of the right ventricle, please refer to Rudski, et al, JASE 2010 July;23(7):685-713

For examples of standard TTE views of the heart, please see figures below.

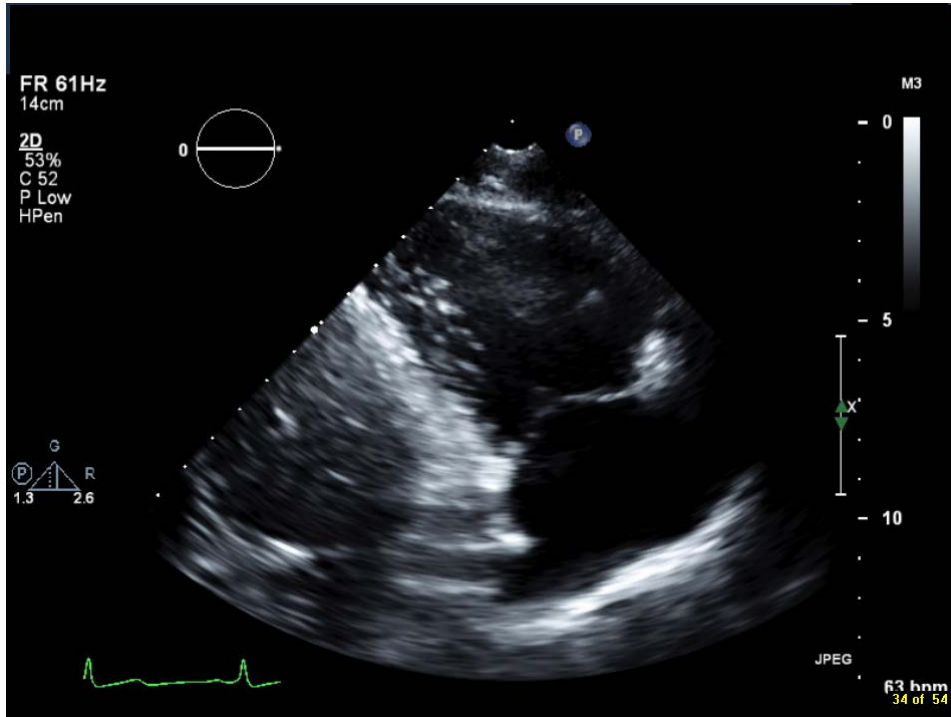
Transducer positions:



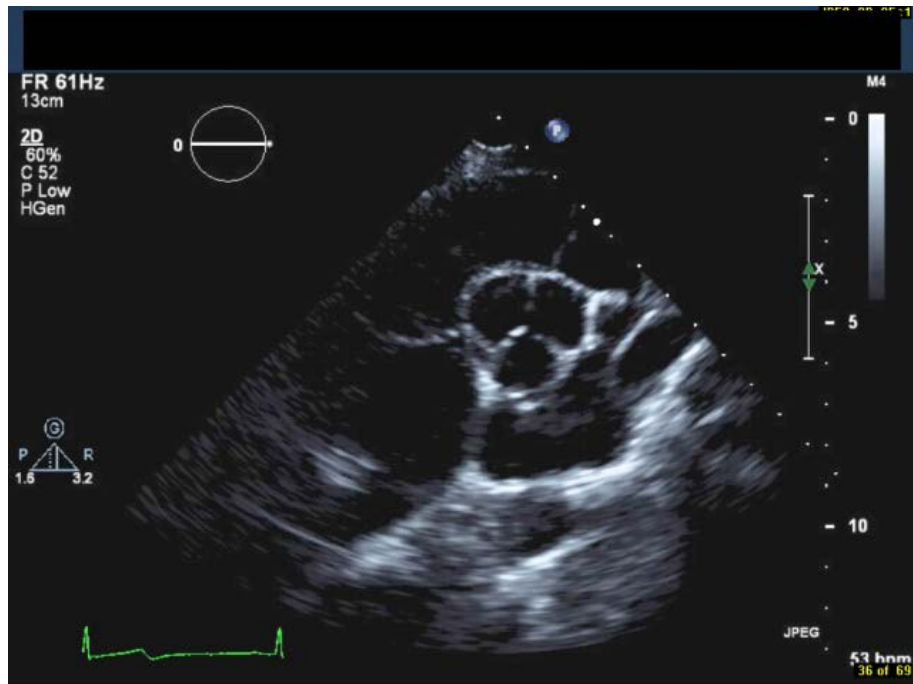
Parasternal long axis (PLAX) view:



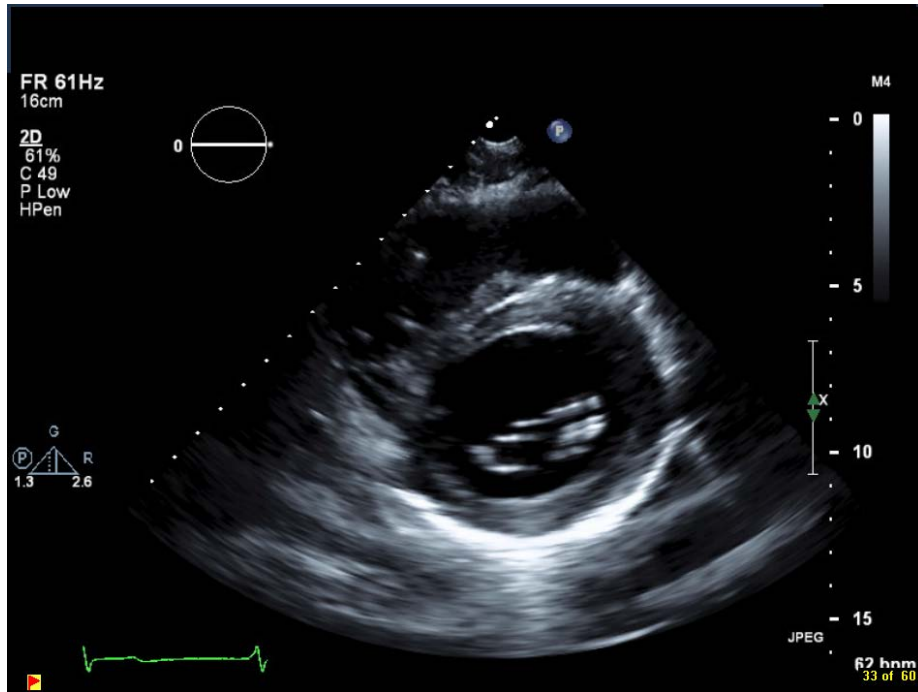
RV inflow view



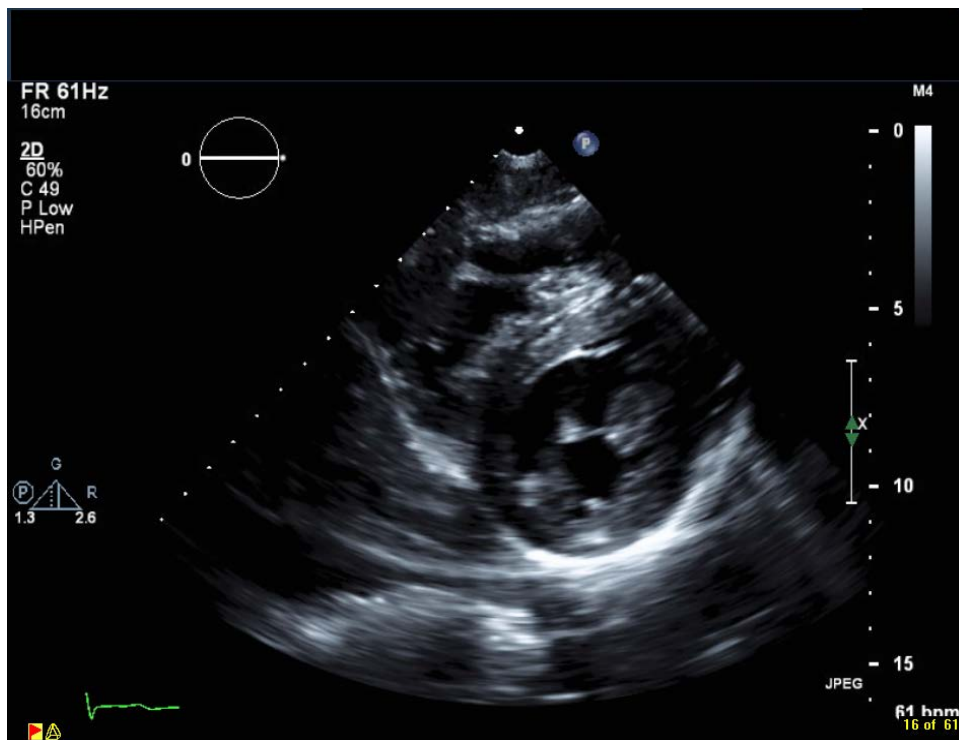
Parasternal short axis view (PSAX) at the RVOT view



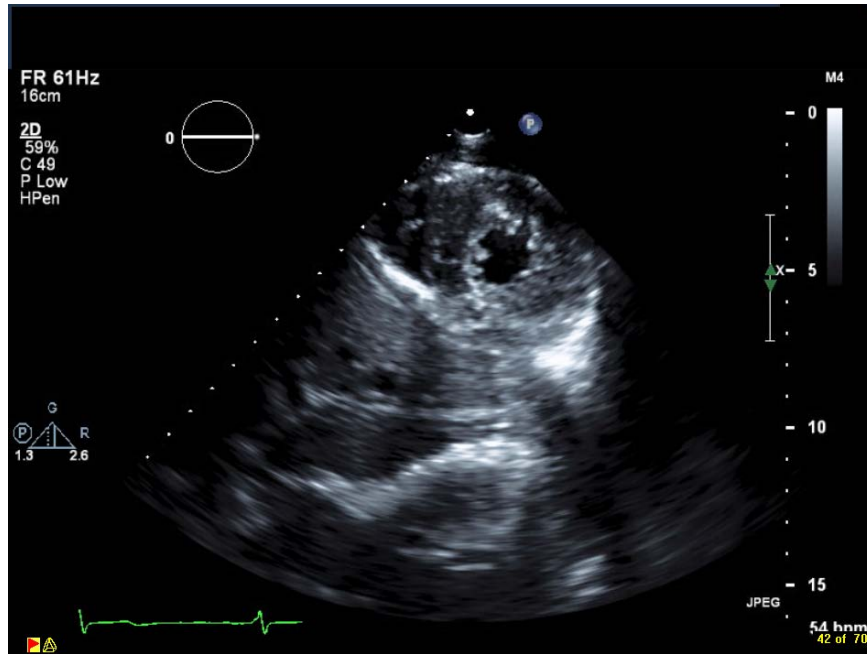
PSAX at the base of the LV (mitral valve level) (note that RV is in view)



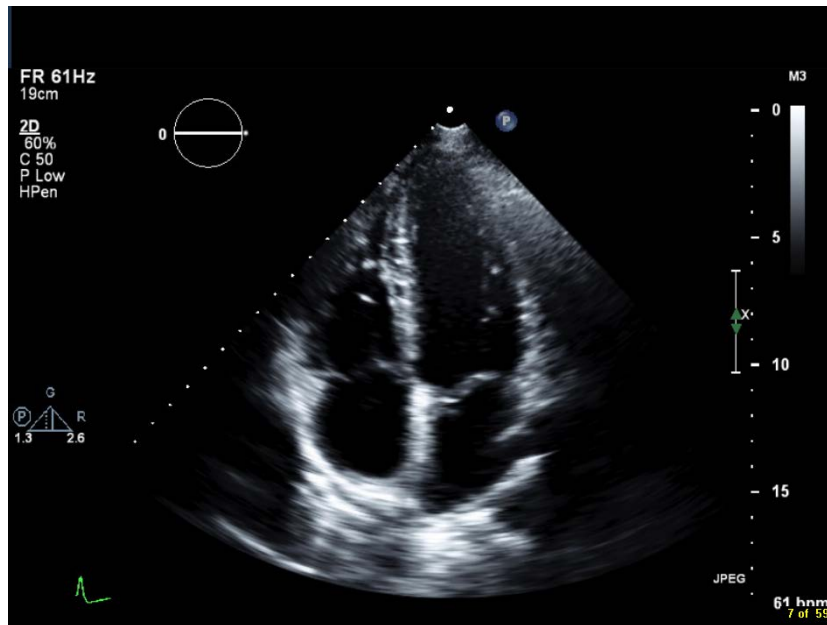
PSAX at the mid ventricular (papillary muscle) level (note that RV is in view)



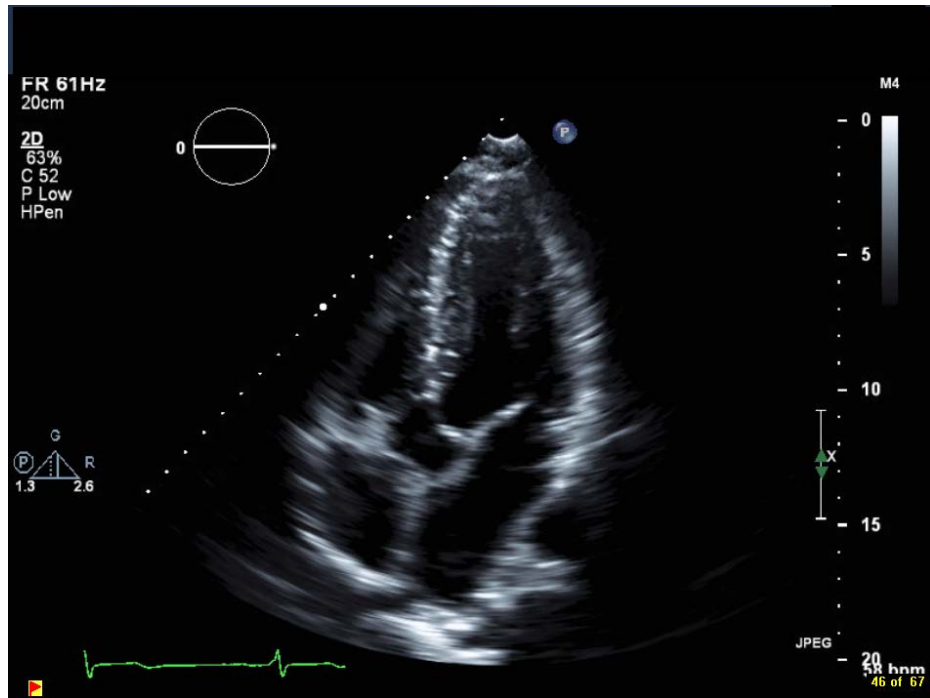
PSAX at the apex (note that RV is in view)



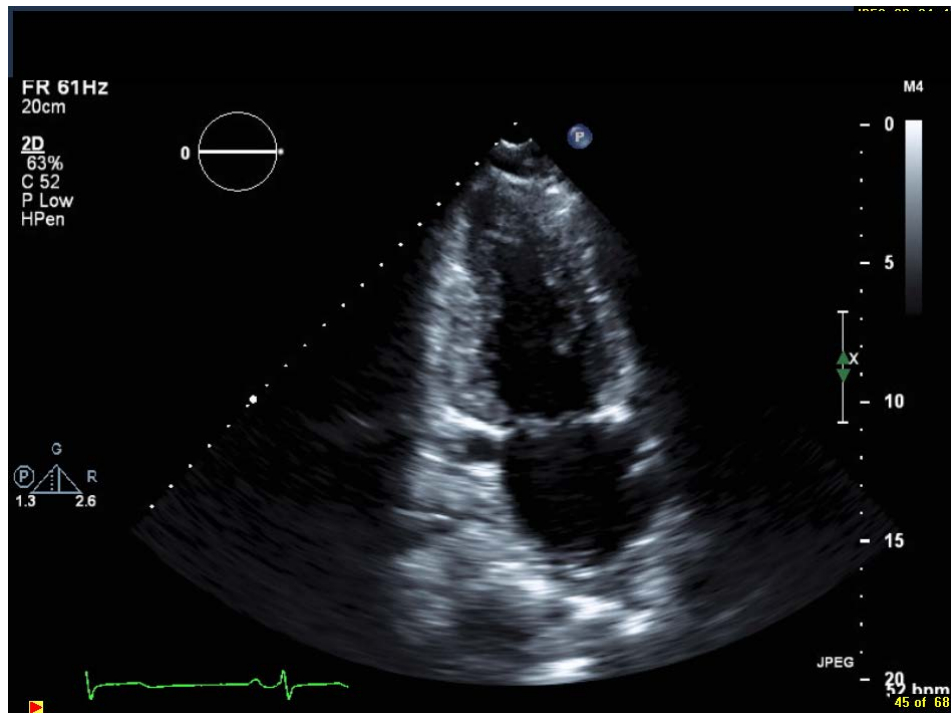
Apical (Ap) 4 chamber view (note that RV free wall is in the view; may need 2 separate loops to optimize endocardial visualization of both chambers if RV is large)



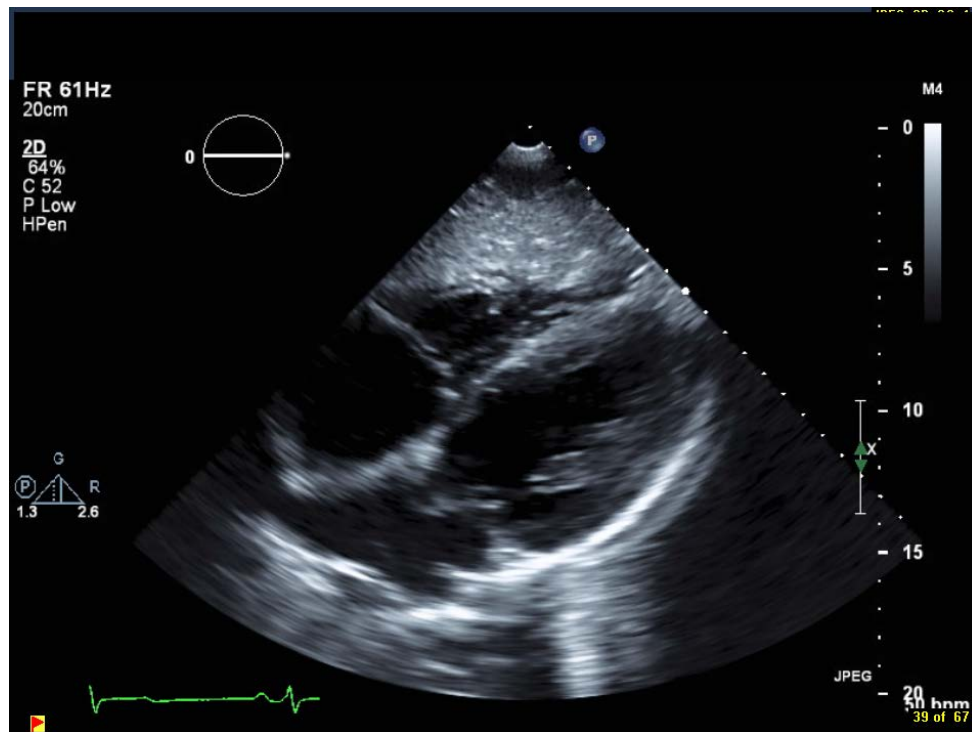
Ap 5 chamber view



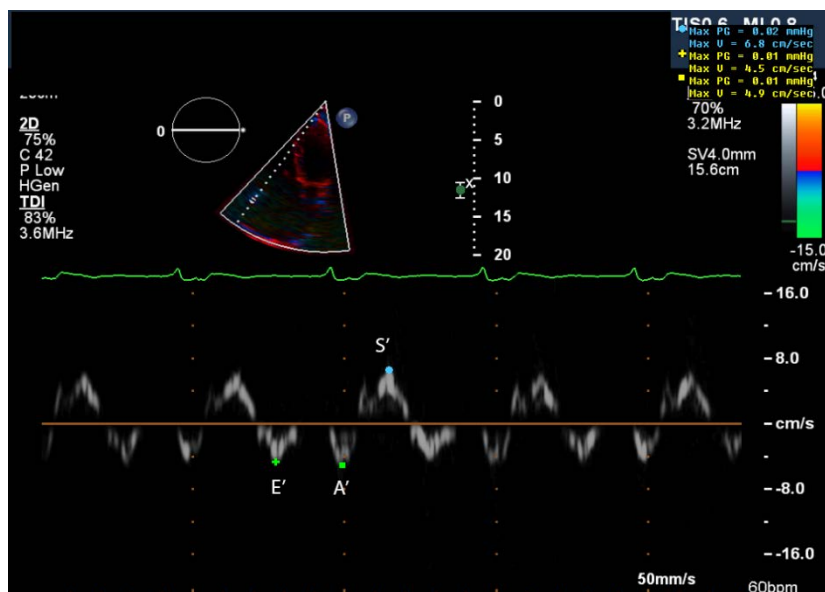
Ap 2 chamber view (note endocardium of both walls visible)



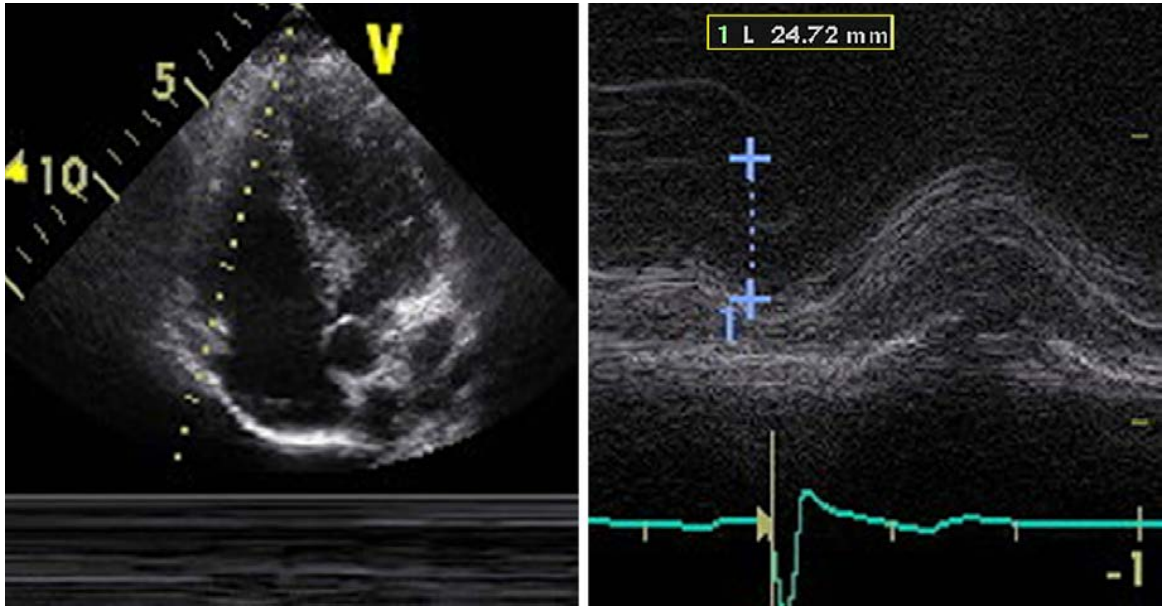
Subcostal 4 chamber/long axis (optimize to not foreshorten the ventricles)



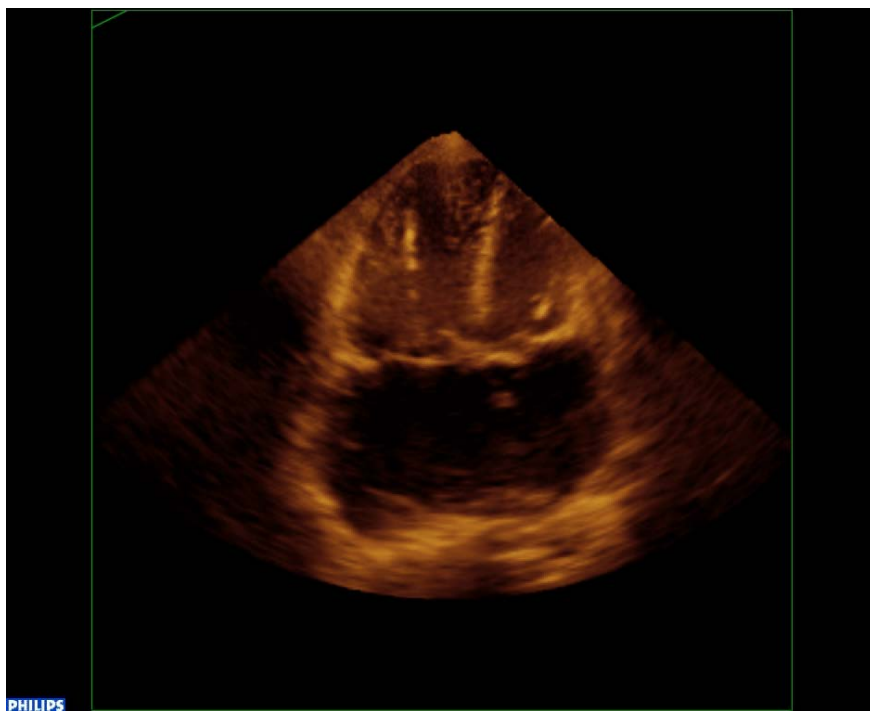
RV free wall annular Tissue Doppler image. Note sample volume in the free wall annulus and that scale and baseline are optimized so both the systolic and the diastolic waves are completely visualized.



TAPSE recording (note location of M-mode sample volume through the free wall annulus and the quality of the M-mode tracing)



3-Dimensional echo recording from the apical 4 chamber view, focused on the Right Ventricle.



**ECHOCARDIOGRAPHY
CHECKLIST FOR ARVC**

1. Parasternal long axis

_____ 2-D imaging: 3 sinus beats focusing on LV/LA/LVOT/Ao
_____ 2-D imaging: 3 sinus beats focusing on the RV
_____ Color Doppler: MV and AoV
_____ M-mode: through the mitral leaflet tips

2. Parasternal Long Axis of the RV inflow (RVIT)

_____ 2-D imaging: 3 sinus beats of the TV leaflets and RV function and wall motion
_____ 2-D zoom: on the RV side of the TV - 3 beats for wall motion and structure (looking for posterior RV wall aneurysms)
_____ Color Doppler: of the TR

3. Parasternal Short Axis at the Base

_____ 2-D imaging: 3 sinus beats of high quality non-focused view
_____ 2-D zoom: Focusing on the RVIT
Focusing on the RVOT
Focusing on the PV/PA
Focusing on the AoV
_____ Color Doppler: RV inflow
RV outflow
Pulm Valve
PA
_____ Spectral Doppler: TR (CW)
PV (CW)

4. Parasternal Short Axis at the Mitral and Tricuspid Valve levels

_____ 2-D imaging: 3 sinus beats to assess wall motion of both LV and RV
Note: ***Frame rates for speckle tracking optimized between 40-80 fps***

5. Parasternal Short Axis at the LV Mid-ventricle (try to have RV and LV in view)

_____ 2-D imaging: 3 sinus beats to assess LV and RV size and wall motion
Note: ***Frame rates for speckle tracking optimized between 40-80 fps***

6. Parasternal Short Axis at the LV Apex (try to have RV and LV in view)

_____ 2-D imaging: 3 sinus beats to assess LV and RV size and wall motion
Note: ***Frame rates for speckle tracking optimized between 40-80 fps***

7. Apical 4 Chamber

_____ 2-D imaging:	3 sinus beats of all 4 chambers for relative size and function
	Note: <i>Frame rates for speckle tracking optimized between 40-80 fps</i>
_____ M-mode:	3 sinus beats focusing on RV
_____ Color Doppler:	3 sinus beats focusing on TV of the lateral (free wall) TV annulus for TAPSE calculation
	Mitral inflow and regurgitation
	Tricuspid Inflow and regurgitation
_____ Spectral Doppler:	CW of MR optimizing scale and gain to see entire envelope
	CW of TR optimizing scale and gain to see entire envelope
	PW of mitral inflow (E and A waves)
	PW of tricuspid inflow (E and A waves)
_____ Tissue Doppler:	of the mitral and tricuspid annulus- free walls and septal (optimize scale and baseline of the image so both systolic and diastolic waves can be measured)
	Note: <i>the frame rate during color TDI is > 140 fps</i>
3-D full volume :	
_____ 4 beat acquisition with entire LV in view avoiding stitch artifacts if possible	
_____ 4 beat acquisition with entire RV in view avoiding stitch artifacts if possible	

8. Apical 5 Chamber

_____ 2-D imaging:	3 sinus beats focusing on LVOT/Aorta
_____ Color Doppler:	Through LVOT/AoV
_____ Spectral Doppler:	LVOT (PW) just below AoV
	Aortic Valve (CW)

9. Apical 2 Chamber

_____ 2-D imaging:	3 sinus beats for LV wall motion
	Note: <i>Frame rates for speckle tracking optimized between 40-80 fps</i>
_____ Color Doppler:	of the MR

10. Apical 2 Chamber of RV

_____ 2-D imaging:	3 sinus beats for RV wall motion
_____ Color Doppler:	of TR

11. Subcostal Long Axis

_____ 2-D imaging:	3 sinus beats to focus on RV free wall and apex function
_____ Color Doppler:	of Interatrial septum and TV/MV

12. Subcostal Short Axis

_____ 2-D imaging:	3 sinus beats to view RVOT and RVIT
_____ Color Doppler:	of TV and PV